

PATIENT

Sampson White

SPECIES

Canine

BREED

Labradoodle

SEX

Male Neutered

AGE

10 years

WEIGHT

58.6lbs

INTERPRETED BY

Maggie Machen
Lamy, DVM
DACVIM (Cardiology)

IMAGING

PERFORMED BY

Pamela Harrigan,
RDCS

HOSPITAL NAME

Norfolk County
Veterinary Service

REFERRING VET

Dr. Ragon

INVOICE

20878

DATE

9/2/21

PRESENTING CLINICAL SIGNS

History: Recheck echo. History chronic valvular disease - Stage B1. Currently, doing well clinically. Need anesthesia for mass removal. BP: 155mmHg.

-Pertinent previous echo findings (7/30/20 MML): LA 2.79 cm; LA:Ao 1.25; LV 4.15 cm; mild LAE; moderate MR; mild TR (2.4 m/s).

ECHOCARDIOGRAM FINDINGS

2D, m-mode, color flow and Doppler imaging is available.

Left ventricle: The LV diameter is mildly dilated with adequate myocardial function. LV wall thicknesses are normal.

Left atrium: The left atrium is moderately dilated.

Mitral valve: The mitral valve is diffusely thickened with no prolapse into the left atrial lumen. Moderate anterior-directed mitral regurgitation with a normal velocity.

Aortic valve/Aorta: The aortic valve is normal in morphology and mobility. Normal aortic outflow velocity; laminar flow. No aortic insufficiency.

Right ventricle: Normal right ventricular diameter and morphology indicating no overt evidence of pulmonary arterial hypertension.

Right atrium: Normal RA dimension.

Tricuspid valve: The tricuspid valve appears mildly thickened with mild tricuspid regurgitation; normal velocity.

Pulmonic valve/Pulmonary artery: The pulmonic valve is normal in morphology and mobility. No pulmonic insufficiency. Normal RVOT velocity; laminar flow.

Pericardium/other: No pericardial or pleural effusion noted. No obvious cardiac masses.

Heart rhythm: ECG reveals a sinus rhythm with an average HR of 120bpm.

2-Dimensional Measurements

| | |
|--------------------|------|
| Ao diam (cm) | 2.2 |
| LA diam (cm) | 4.0 |
| LA:Ao (Swe) | 1.8 |
| IVS thickness (cm) | 0.85 |
| LVID diastole (cm) | 4.7 |
| PW thickness (cm) | 0.8 |
| LVID systole (cm) | 3.3 |
| FS (%) | 30 |

Doppler Measurements

| | |
|----------------|------|
| PV Vmax (m/s) | 0.74 |
| AoV Vmax (m/s) | 1.6 |
| MR Vmax (m/s) | 5.0 |
| TR Vmax (m/s) | 2.3 |
| TR PG (mmHg) | 20 |

INTERPRETATION OF THE FINDINGS

Chronic degenerative valve disease persists with evidence of progression. Previously mild LA dilation is now moderate, and the LV is mildly increased as well. This is concerning for progressive issues going forward, and Pimobendan is warranted at this juncture. In an asymptomatic dog no additional medications are clearly indicated at this time, however close monitoring at home is advised. Prognosis is guarded at this stage (B2), with risk for spontaneous CHF, development of arrhythmias, LA tear and/or sudden death going forward.



PATIENT

Sampson White

SPECIES

Canine

BREED

Labradoodle

SEX

Male Neutered

AGE

10 years

WEIGHT

58.6lbs

INTERPRETED BY

Maggie Machen
 Lamy, DVM
 DACVIM (Cardiology)

IMAGING PERFORMED BY

Pamela Harrigan,
 RDCS

HOSPITAL NAME

Norfolk County
 Veterinary Service

REFERRING VET

Dr. Ragon

INVOICE

20878

DATE

9/2/21

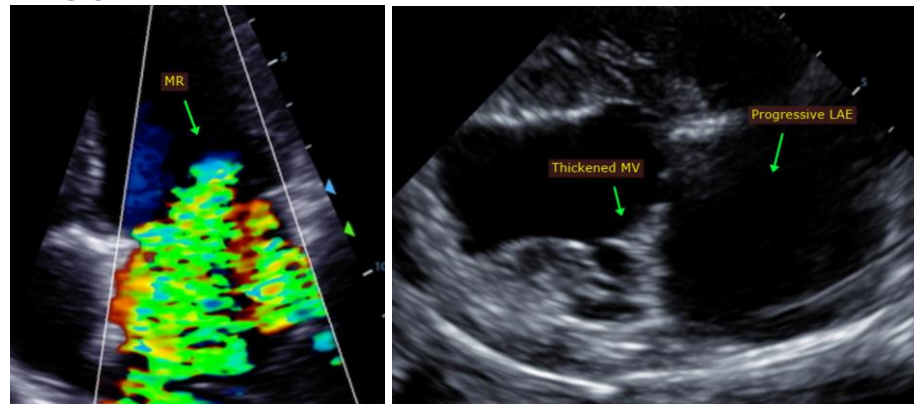
RECOMMENDATIONS

- Institute Pimobendan 0.2-0.3mg/kg PO q12h.
- Omega fatty acid supplementation and mild salt restriction may be of some long-term benefit.
- Once on Pimobendan for 3-5 days, anesthetic risk is considered mildly elevated. Cardiac protective drug choices (opioid/benzodiazepine premedication, propofol or alfaxalone induction, isoflurane gas) are recommended. Pre-oxygenate for 5-10 minutes prior to induction. Monitor for arrhythmias, hypotension, and hypoxia both intra and post-operatively and intervene as necessary. Mild IV fluid restriction is recommended to avoid fluid overload. Avoid heart rate stimulating drugs such as atropine unless clinically indicated.
- Monitor for development of a cough, labored breathing, exercise intolerance or collapse episodes. Monitoring of sleeping breathing rates is recommended to screen for CHF at home.

PLAN

- Recommend conservative monitoring with a recheck echocardiogram in 6 months, sooner if any development of clinical signs.

IMAGES



The information and recommendations provided are based on the images presented by the referring veterinarian. No evaluation can be communicated regarding pathology that was not visible in the image/video clips provided.

Thank you for this referral. This report was generated using transcription software, and minor dictation errors may be present. If the clinical or image interpretation does not parallel your findings or if I can be of any further assistance please contact me.

Maggie Machen Lamy, DVM
Diplomate of the American College of Veterinary Internal Medicine (Cardiology)
 info@sonopath.com